



# Feasibility and safety of transbronchial lung cryobiopsy and mediastinal lymph node cryobiopsy: Experience from a resource-limited African setting

A Esmail,<sup>\*1</sup> MD, FCP, Cert Pulmonology (SA), PhD ; K Tsoka,<sup>\*1</sup> MB ChB, FCP;  
R Hofmeyr,<sup>2</sup> MB ChB, MMed (Anaes), FCA, FAMW, FEAMS ; J Chokoe Maluleke,<sup>\*3,4</sup> BSc, MB ChB, MMed (Path) ;  
H Donson,<sup>1</sup> ND Clin (Resp & Crit Care), BTech Clin Tech, NHD PSE; R Roberts,<sup>\*3,4</sup> MB ChB; T Pennell,<sup>5</sup> MB ChB;  
N Vorajee,<sup>1</sup> MB ChB, FCP, Cert Pulmonology (SA); M Emhemed,<sup>1</sup> MB ChB, FCP, Cert Pulmonology (SA);  
S Eknewir,<sup>1</sup> MB ChB, FCP, Cert Pulmonology (SA); B Mbena,<sup>1</sup> MB ChB, FCP, Cert Pulmonology (SA);  
K Dheda,<sup>1,6</sup> MB ChB, FCP, Cert Pulmonology (SA), PhD

\*Contributed equally; names listed in order of seniority.

<sup>1</sup> Centre for Lung Infection and Immunity, Division of Pulmonology, Department of Medicine, Faculty of Health Sciences, University of Cape Town; University of Cape Town Lung Institute; SAMRC Centre for the Study of Antimicrobial Resistance, University of Cape Town, South Africa

<sup>2</sup> Department of Anaesthesia and Perioperative Medicine, Faculty of Health Sciences, University of Cape Town and Groote Schuur Hospital, Cape Town, South Africa

<sup>3</sup> Division of Anatomical Pathology, Department of Pathology, Faculty of Health Sciences, University of Cape Town, South Africa

<sup>4</sup> National Health Laboratory Service, Groote Schuur Hospital, Cape Town, South Africa

<sup>5</sup> Division of Cardiothoracic Surgery, Department of Surgery, Groote Schuur Hospital, Cape Town, South Africa

<sup>6</sup> Faculty of Infectious and Tropical Diseases, Department of Immunology and Infection, London School of Hygiene and Tropical Medicine, UK

Corresponding author: K Dheda (keertan.dheda@uct.ac.za)

**Background.** Transbronchial lung cryobiopsy (TBLC) is a relatively new technique recommended for sampling of lung parenchyma in patients with suspected interstitial lung disease (ILD) and as an alternative to surgical lung biopsy. A more recently introduced technique is endobronchial ultrasound-guided transbronchial mediastinal lymph node cryobiopsy (EBUS-TMC) to enable tissue biopsy of mediastinal lymph nodes. However, there are no data on the feasibility of implementing these techniques in a resource-limited African setting, where there is a chronic bed shortage and same-day discharges are preferable.

**Objectives.** To determine the feasibility and diagnostic yield of TBLC and EBUS-TMC in a resource-limited African setting.

**Methods.** We performed an audit of lung and lymph node cryobiopsy procedures performed at the E16 Respiratory Clinic at Groote Schuur Hospital, Cape Town, South Africa. Indications, diagnostic performance outcomes and lessons learned were documented and analysed.

**Results.** Sixteen patients underwent 19 cryobiopsy procedures that were performed under general anaesthesia ( $n=11$  TBLC,  $n=8$  EBUS-TMC, including 3 patients in whom both TBLC and EBUS-TMC were concurrently performed). The main indications were evaluation of ILD and suspected lymph node malignancy. The diagnostic yield was 63.6% for TBLC ( $n=7/11$ ; 2 nonspecific interstitial pneumonia, 2 sarcoidosis, 1 respiratory bronchiolitis-ILD, 1 organising pneumonia, 1 nonspecific chronic inflammation) and 50.0% for EBUS-TMC ( $n=4/8$ ; 1 plasmacytoma, 1 lymphoma, 1 cryptococcus infection, 1 patient with both cryptococcus infection and tuberculosis). Of the patients, 2 had moderate bleeding and 3 had mild bleeding, and 14 were discharged on the day of the procedure.

**Conclusion.** TBLC and EBUS-TMC, with avoidance of surgical lung biopsy in most patients and same-day discharge in most patients, are feasible in an African setting. These data inform clinical practice and programme implementation in resource-limited settings.

**Keywords.** Transbronchial lung cryobiopsy (TBLC), endobronchial ultrasound-guided transbronchial mediastinal lymph node cryobiopsy (EBUS-TMC), interstitial lung disease (ILD), interventional pulmonology.

*Afr J Thoracic Crit Care Med* 2025;31(1):e2448. <https://doi.org/10.7196/AJTCCM.2025.v31i1.2448>

## Study synopsis

**What the study adds.** Although transbronchial lung cryobiopsy (TBLC) is widely accessible in resource-rich settings such as Europe and the USA, there are no data from resource-limited African settings. Endobronchial ultrasound-guided transbronchial mediastinal lymph node cryobiopsy (EBUS-TMC) is a newer technique for which there are limited data. We provide feasibility and implementation data from an African setting.

**Implications of the study.** We provide useful programmatic implementation data for resource-limited African settings and show that implementation of these techniques with same-day discharge is feasible in a setting where there is limited access to overnight beds and anaesthetic support. Important implementation lessons learned that will facilitate initiation of a new TBLC/EBUS-TMC service are outlined.

Interstitial lung disease (ILD) is a common clinical problem faced by pulmonologists. Depending on the clinical context, the initial approach involves transbronchial lung biopsy, especially in resource-limited settings. However, diagnostic performance is suboptimal, with a diagnosis achieved in only ~30% of patients owing to the anatomically small volume of biopsy tissue obtained and the associated crush artifact.<sup>[1-3]</sup> An alternative is image-guided percutaneous biopsy, where the diagnostic yield is ~40 - 50%, but access to such expertise in resource-limited settings is limited, and pneumothorax rates are high (20 - 45%).<sup>[4,5]</sup> Another alternative is surgical lung biopsy, but patients need to be admitted for several days, it is costly, and there is associated mortality and a 5 - 15% complication rate (bleeding, significant air leak, substantial thoracic pain, cardiac arrhythmias and infectious complications).<sup>[6,7]</sup>

A more recently available alternative is transbronchial lung cryobiopsy (TBLC), which involves insertion of a cryoprobe via the airways into the lung periphery under screening, generally in an intubated patient. As a precaution to tamponade any bleeding, an endobronchial blocker is also inserted into the segment of interest, and inflated once the cryoprobe and associated lung tissue are removed<sup>[8]</sup> (Fig. 1). The moist lung tissue adheres to the tip of the cryoprobe, which is cooled to ~-80°C using pressurised carbon dioxide.<sup>[9]</sup> A significant body of evidence, summarised in a systematic review, showed that the procedure is useful, with a diagnostic yield of ~80% compared with surgical lung biopsy, which has a diagnostic yield of ~95%.<sup>[10]</sup> The ~15% lower diagnostic yield compared with surgical lung biopsy is a trade-off for same-day discharge, lower morbidity rates and lower mortality. This systematic review and meta-analysis incorporated 43 studies and showed that TBLC has a diagnostic yield of 81% v. 94% for video-assisted thorascopic surgical (VATS) lung biopsy.<sup>[10]</sup> Significant bleeding was encountered in 6.9% of cases and pneumothorax in 5.6%, while acute exacerbation of the underlying ILD occurred in 1.4%. Mortality was 0.6% v. 1.7% for VATS lung biopsy.<sup>[10]</sup>

The European Respiratory Society has now produced guidance recommending the use of TBLC for the diagnosis of ILD.<sup>[11]</sup> While this procedure has been adopted on several continents, there are no data on its feasibility in a resource-limited African setting, which has unique challenges that include severe bed shortages, budget cuts limiting access to surgical lung biopsy, limited access to anaesthetic support, and severely limited access to cardiothoracic procedures, which are generally available only in large cities. Whether this technique is feasible and implementable in a resource-limited African setting therefore remains unclear. To address this knowledge gap, we reviewed our experience of this technology, which was introduced at a tertiary care hospital in Cape Town, South Africa, in July 2024.

Additionally, endobronchial ultrasound-guided transbronchial mediastinal lymph node cryobiopsy (EBUS-TMC) has been undertaken across several centres to obtain better samples from mediastinal lymph nodes and masses.<sup>[12,13]</sup> In this procedure, after undertaking EBUS transbronchial needle aspiration (EBUS-TBNA), a cryoprobe is inserted into the lymph node and a tissue sample is extracted. Current experience suggests that this technique is suitable when rapid on-site cytological analysis (ROSE) fails to provide a diagnosis, but additionally where histological analysis of tissue architecture may be useful, e.g. in malignancies such as

lymphoproliferative disorders and in benign conditions such as sarcoidosis where obtaining tissue is often useful. Given the unique clinical context and challenges outlined above, we also reviewed our experience with this newer technique.

## Methods

### TBLC

Patients were referred for TBLC following a multidisciplinary meeting of radiologists, pulmonologists and cardiothoracic surgeons. All patients had ILD for which a cause needed to be ascertained, and histological examination was therefore required. Permission for use of the anonymised data for this study was provided by the University of Cape Town Research Ethics Committee (ref. no. UCT HREC REF 028/2023). Key demographic and clinical variables were captured on a database. All procedures were done under general anaesthesia in the bronchoscopy suite of the E16 Respiratory Clinic at Groote Schuur Hospital. Total intravenous anaesthesia was initiated and maintained with target-controlled infusions of propofol and remifentanyl, with pressure-controlled mechanical ventilation. Depending on patient characteristics, a supraglottic airway (SGA) or endotracheal tube (ETT) was inserted. Using the included multiport adaptor, an Arndt endobronchial blocker (Cook Medical, USA) was guided through the SGA or ETT with the bronchoscope. In some cases, patients were intubated with a Univent ETT (Teleflex Medical, USA), which contains an accessory channel accommodating the bronchial blocker, obviating the need for insertion of the bronchial blocker and the bronchoscope within the same endotracheal lumen.

The bronchial blocker was placed at the entrance of the subsegment of interest. The lung cryobiopsy probe attached to the controller (ERBECRYO 2; Erbe Elektromedizin GmbH, Germany, paired with a single-use 1.1 mm probe) was advanced distal to the bronchial blocker and to the lung periphery using fluoroscopic screening (see Fig. 1 for an overview). A freeze time of ~5 - 8 seconds was used, depending on the quality of samples retrieved (starting at 5 seconds with incremental increases in freeze time, with a maximum freeze time of 10 seconds). The samples obtained were sent for histopathological analysis in formalin, and for microbiological examination, polymerase chain reaction and culture for *Mycobacterium tuberculosis* where indicated (GeneXpert MTB/RIF Ultra; Cepheid, USA).

### EBUS-TBNA

In 3 patients who underwent TBLC, EBUS-TMC was also performed after EBUS-TBNA. However, in 5 patients only EBUS-TMC was performed after EBUS-TBNA (i.e. TBLC was not performed; see Fig. 2 for a study plan).

EBUS-TBNA was performed using an Olympus EBUS bronchoscopy system (EVIS EXERA III platform BF-190, EU-ME2 ultrasound processor and BF-UC190F endobronchial ultrasound bronchoscope; Olympus Medical Systems, USA), and a pathologist and a medical technologist were present for ROSE. A 19-gauge EBUS needle (ViziShot 2 EBUS-TBNA; Olympus Medical Systems, USA) was used, and the node was sampled using ~4 - 6 passes prior to insertion of the 1.1 mm single-use cryoprobe into the lymph node though the tract created by the 19G needle. An associated EBUS balloon was inflated for better imaging when required to facilitate

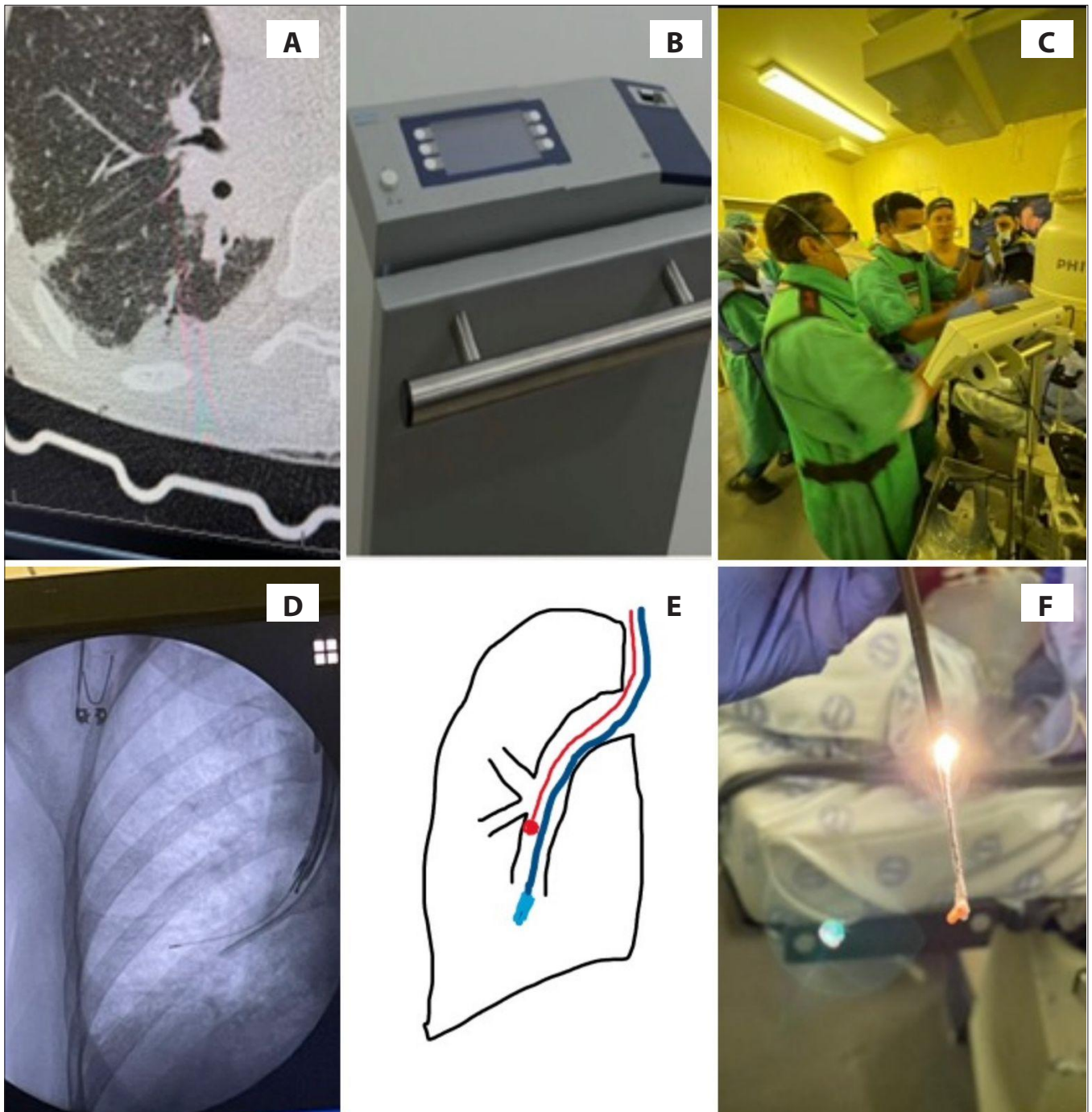


Fig. 1. (A) Suspected interstitial lung disease confirmed on imaging. (B) Cooled cryoprobe control module. (C) Multidisciplinary team of pulmonologists, radiographers and pulmonary technicians carrying out the procedure. (D) Cryoprobe passed through the end of the bronchoscope under screening distal to the bronchial blocker. (E) Sketch outlining the relationship of the uninflated bronchial blocker and the cryoprobe. (F) Extracted tissue sample at the end of the cryoprobe to be sent for histological examination.

better apposition to the airway. After completion of the EBUS-TBNA, and if a diagnosis was not evident on cytological examination, the cryoprobe was inserted through the same needle tract to access the lymph node under ultrasound guidance. When access through the tract was difficult, a biopsy forceps (M00546270; Boston Scientific, USA) was used to widen the tract to enable easier introduction of the cryoprobe. Approximately 3 - 5 lymph node cryobiopsy samples were obtained using a freeze time of ~7 seconds.

## Results

There were 16 patients selected, and 19 cryobiopsies were performed (3 patients underwent both TBLC and EBUS-TMC), with an equal distribution of males and females. The median age was 58 (95% CI 36.2 - 66.1) years. Eleven patients (57.9%) were smokers (median of 22.5 pack-years). Baseline comorbidities included hypertension ( $n=9$ ; 47.4%), followed by diabetes mellitus ( $n=6$ ; 31.6%). The most common indication reported for TBLC was ILD ( $n=9$ ; 81.8%), with suspected

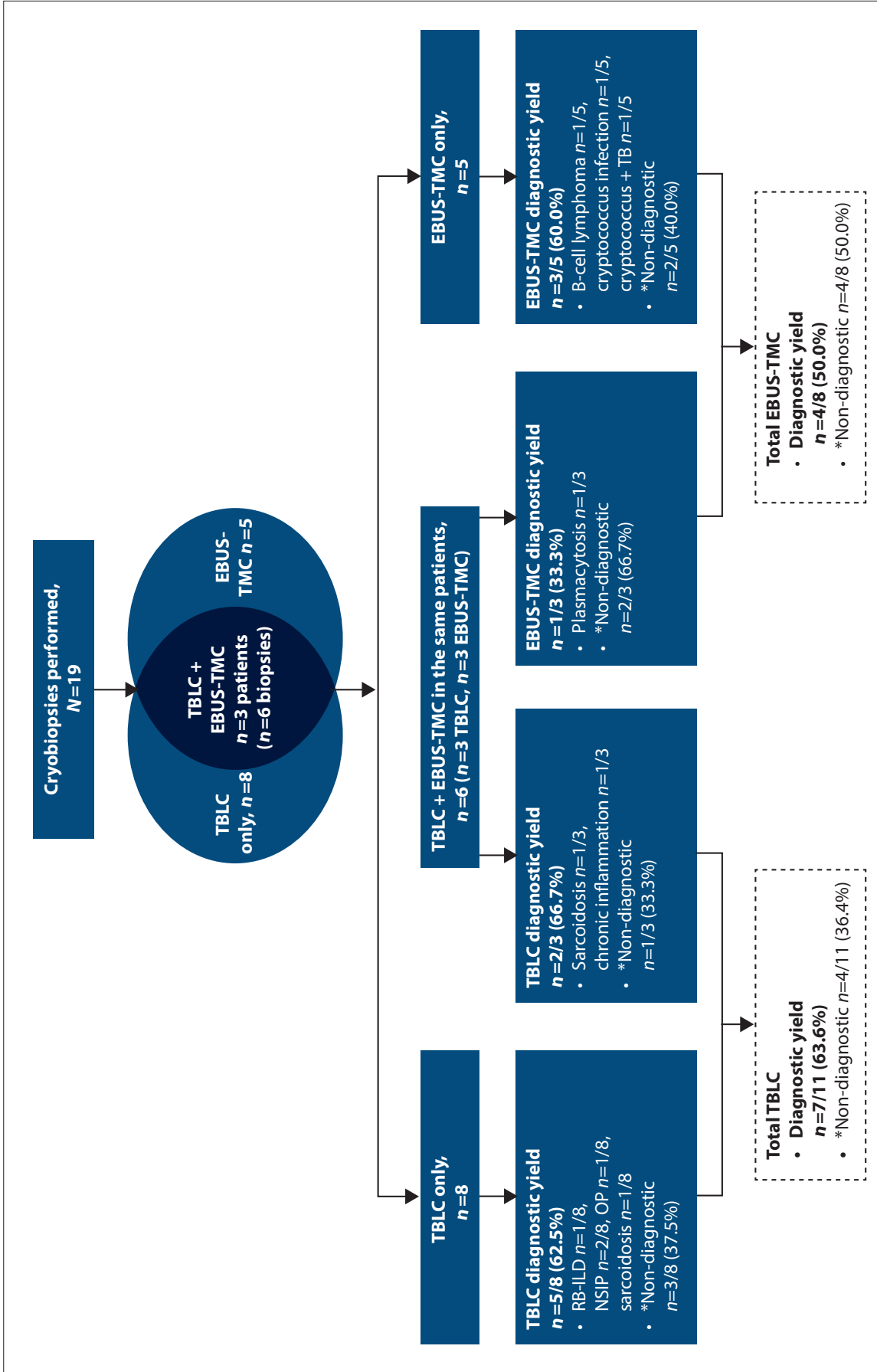


Fig. 2. Study overview demonstrating patient selection and distribution of types of cryobiopsy (TBLC, TBLC + EBUS-TMC, and EBUS-TMC alone). (TBLC = transbronchial lung cryobiopsy; EBUS-TMC = endobronchial ultrasound-guided transbronchial lymph node cryobiopsy; RB-ILD = respiratory bronchiolitis-interstitial lung disease; NSIP = nonspecific interstitial pneumonia; OP = organising pneumonia; \*Non-diagnostic = suboptimal or insufficient amount of tissue and benign tissue.)

**Table 1. Demographic and clinical characteristics of the study participants who underwent cryobiopsy procedures\***

Characteristic	EBUS-TMC ( <i>n</i> =8), <i>n</i> (%) <sup>†</sup>	TBLC ( <i>n</i> =11), <i>n</i> (%) <sup>†</sup>	Total ( <i>N</i> =19), <i>n</i> (%) <sup>†</sup>
Age (years), median	53	58	58
Sex			
Male	4 (50.0)	5 (45.5)	9 (47.3)
Female	4 (50.0)	6 (54.5)	10 (52.6)
Comorbidities			
HIV	2 (25.0)	0	2 (10.5)
Cancer	1 (12.5)	1 (9.1)	2 (10.5)
Connective tissue disease	0	2 (18.2)	2 (10.5)
Hypertension	3 (37.5)	6 (54.5)	9 (47.4)
Diabetes mellitus	3 (37.5)	3 (27.3)	6 (31.6)
Dyslipidaemia	1 (12.5)	2 (18.2)	3 (15.8)
Chronic lung disease	2 (25.0)	2 (18.2)	4 (21.1)
Smokers	5 (62.5)	6 (54.5)	11 (57.9)
Pack-years, median	20	27.5	22.5
Indication			
Suspected malignancy	4 (50.0)	3 (27.3)	7 (36.8)
Interstitial lung disease	2 (25.0)	9 (81.8)	11 (57.9)
Tuberculosis	2 (25.0)	3 (27.3)	5 (26.3)
Other (fungal)	1 (12.5)	1 (9.1)	2 (10.5)
Complication			
Yes	2 (25.0)	7 (63.6)	9 (47.4)
No	6 (75.0)	4 (36.4)	10 (52.6)
Intraoperative complications			
Moderate bleeding	0	2 (18.2)	2 (10.5)
Minimal bleeding	0	3 (27.3)	3 (15.8)
Pneumothorax	0	1 (9.1)	1 (5.3)
Pneumomediastinum	1 (12.5)	0	0
Hypercapnia	1 (12.5)	1 (9.1)	2 (10.5)

EBUS-TMC = endobronchial ultrasound-guided transbronchial mediastinal lymph node cryobiopsy; TBLC = transbronchial lung cryobiopsy.

\*A total of 19 cryobiopsies were undertaken in 16 patients; 3 patients had both TBLC and EBUS-TMC. Demographic characteristics are reported for each procedure.

<sup>†</sup>Except where otherwise indicated.

malignancy and suspected tuberculosis (TB) accounting for 7 (36.8%) and 5 (26.3%) of the referred patients, respectively (Table 1).

In total, 11 TBLC procedures were performed: 2 patients were diagnosed with sarcoidosis, 4 with ILD (2 had nonspecific interstitial pneumonia, 1 organising pneumonia, and 1 respiratory bronchiolitis-ILD), and 1 with chronic nonspecific inflammation. Four procedures (4/11; 36.4%) were non-diagnostic (Fig. 2).

A total of 8 EBUS-TMC biopsies were performed (after a non-diagnostic EBUS-TBNA): in 4, a diagnosis was obtained (cryptococcus infection, plasmacytosis, B-cell lymphoma, and a patient with both cryptococcus and TB), and 4 were non-diagnostic. All mediastinal lymph nodes targeted by EBUS-TMC measured between 15 - 30 mm in the largest plane on endobronchial ultrasound.

There was moderate bleeding in 2 patients, who required instillation of 3 aliquots of 1:20 000 (diluting a 1 mg (1:1 000) adrenaline ampoule to 20 mL with sterile water) adrenaline flushes and recurrent inflation of the balloon blocker, while 3 patients had mild bleeding that was controlled with use of the balloon blocker. One patient had a pneumothorax following TBLC which was managed conservatively, with discharge the next day, and another had pneumomediastinum after EBUS-TMC. He was also managed conservatively and

hospitalised for 72 hours to monitor the pneumomediastinum to its resolution. The latter patient was recruited in the initial phase, during which we had little control of the depth of the cryoprobe, but in the patients recruited later we marked the cryoprobe to prevent over-insertion of the probe beyond the lymph node (Box 1).

## Discussion

To the best of our knowledge, this is the first report outlining initial experience with TBLC and EBUS-TMC in a resource-limited African centre. The key findings were: (i) both TBLC and EBUS-TMC were feasible in our setting; (ii) the majority of patients with severe and extensive ILD achieved same-day discharge without any major complications; and (iii) the diagnostic yield of TBLC was ~64% and that of EBUS-TMC 50%, although the sample size was small.

Initiation and implementation of the lung and lymph node cryobiopsy programme was feasible in our setting and obviated admission for 14/16 patients (87.5%) (i.e. these patients were discharged on the same day), with 1 patient with a non-diagnostic TBLC requiring surgical lung biopsy after MDT discussion, while 3 other patients were managed as per the recommendation of the MDT. This was critical in our clinical context because of a severe shortage

of admission beds, budget cuts limiting the volume of surgical procedures, and limited access to anaesthesia support. The situation has recently worsened further because of budget-related austerity measures introduced in the hospital. A surgical lung biopsy approach would have required admission of all 16 patients, with hospital stays of between 5 and 7 days in each case, and potential complications in some of these patients may have included infection, bleeding, significant air leak, etc.<sup>[7]</sup> Routine post-bronchoscopic observation in the bronchoscopic recovery area was adequate in all the patients who underwent biopsy. Although we did not directly evaluate costs per patient, circumventing theatre use and several days of admission makes TBLC and EBUS-TMC much more cost-effective procedures. Indeed, despite the ~15 - 20% lower diagnostic yield of TBLC compared with VATS lung biopsy,<sup>[10]</sup> studies have shown that TBLC has better setting-specific cost-effectiveness.<sup>[14]</sup> Like TBLC, surgical lung biopsy is also prone to sampling error, but much less so owing to the larger size of the biopsy specimen and the lack of crush artifact.<sup>[2,15]</sup> Interestingly, the optimal area to biopsy (ground-glass shadowing v. honeycombing) remains unclear and is currently a subject of further study.

In our study, of the 11 TBLCs performed, 4 were non-diagnostic (1 specimen showed normal alveoli and was therefore from an area with no pathology, 2 showed bronchial tissue only, and 1 showed fragments of bronchus and was therefore non-representative). Our sample size was too small to make any inferences about the reasons for the non-diagnostic results. We did not encounter significant complications in the patients who underwent TBLC. However, we used a 1.1 mm probe, and recent data indicate that complication rates with this smaller probe are significantly lower because of the smaller pieces of tissue that are extracted. Recent data also showed that the low complication rate using the 1.1 mm probe means that use of a supraglottic airway may be acceptable.<sup>[16]</sup> A recent randomised controlled trial from India showed that when a 1.9 mm probe was used it was possible to undertake the procedure using conscious sedation.<sup>[17]</sup>

We found that undertaking EBUS-TMC was also feasible. However, we learned important lessons on how to conduct the procedure efficiently (Box 1). Accessing the lymph node with the cryoprobe can be challenging when the tracheal or bronchial wall is thick and resistant, and we therefore occasionally used biopsy forceps to widen or enlarge the biopsy tract. Nevertheless, 4 of the 8 lymph nodes sampled were non-diagnostic (3 were unsatisfactory samples, and 1 showed benign tissue). Patient selection in this context is important; published data have shown that EBUS-TMC has ~10% better yield than EBUS-TBNA, and the specific advantage is in cases where a tissue diagnosis/architecture is required, e.g. in patients with lymphoproliferative malignancies, haematological malignancies, and benign disorders such as sarcoidosis. In our context, we only subjected patients with enlarged mediastinal nodes of at least 15 mm to the EBUS-TMC procedure when their conventional EBUS was non-diagnostic or if lymphoma was suspected. Furthermore, EBUS-TMC may also be useful in cases when EBUS-TBNA does not provide sufficient material for genomic analysis to enable the selection of specific immunotherapy/targeted therapy for lung cancer.<sup>[12]</sup>

Our study was limited by the small sample size, and conclusions about diagnostic yield in our setting would therefore be unreliable. However, our key objective was not to ascertain diagnostic yield or complication rates, but to determine the feasibility of implementing

#### Box 1. Lessons learned from initiating a TBLC and EBUS-TMC programme

- Pre-discussion and negotiation with the anaesthesia team are essential in an environment where there is a shortage of anaesthesiologists and operating theatre time.
- Cardiothoracic support is important in case of complications such as severe bleeding.
- Choice of a bronchoscope of appropriate diameter and use of a large enough endotracheal tube are essential in order to accommodate both the bronchoscope and the bronchial blocker within the ETT or SGA lumen. We used bronchoscopes with 2.2 mm and 2.8 mm working channels, but the critical factor for fit through the airway device is the *external* diameter of the bronchoscope. The sum of the external diameters of the bronchoscope and blocker should not exceed 80 - 90% of the internal diameter of the ETT or SGA, of which the latter usually has a larger internal diameter. Owing to the shared airway, we used a bronchoscope with a 2.2 mm working channel with a smaller ETT because of the extremely tight fit, and a bronchoscope with a larger 2.8 mm channel was used with the SGA. The Arndt endobronchial blocker is available in three diameters (5, 7 and 9Fr). While the 5Fr offers the smallest external diameter (~1.6 mm), it may not have sufficient length to block distal subsegments in all patients; the 7Fr (external diameter ~2.3 mm) is a good compromise.
- Use of ETTs with a dedicated bronchial blocker mounted in a side channel (e.g. Univent tube) is advantageous, as it allows easier passage of the scope in the absence of competition for space with the blocker.
- Experimentation is required to obtain the optimal cryoprobe freeze time depending on the type of tissue being biopsied.

complex interventional procedures in a resource-limited setting where anaesthesia services and bed capacity are extremely limited, and to outline the lessons learned for the benefit of other centres that may wish to initiate TBLC and/or EBUS-TMC.

## Conclusion

TBLC and EBUS-TMC can provide useful diagnostic information, and both are feasible in a resource-limited setting, allowing for same-day discharge without the need for surgical lung biopsy in selected patients. EBUS-TMC allows for improved tissue sampling in selected cases where histological tissue architecture is important, such as in lymphoma and sarcoidosis. Our data will be useful for centres in resource-limited settings in Africa and elsewhere that are attempting to implement a programme incorporating TBLC and/or EBUS-TMC. Valuable lessons were learned in setting up this service, and there is a clear need to expand it.

**Data availability.** The datasets generated and analysed during the present study are available from the corresponding author (KD) on reasonable request. Any restrictions or additional information regarding data access can be discussed with the corresponding author.

**Declaration.** AE, TP and KD are members of the editorial board. The research for this study was done in partial fulfilment of the requirements for KT's MPhil degree at the University of Cape Town.

**Acknowledgements.** We thank Erbe Elektromedizin GmbH for providing training on the use of equipment, our patients who formed part of this research, and the administration of Groote Schuur Hospital for facilitating this research.

**Author contributions.** AE, KT and KD conceived the trial design; AE, KT, KD, RH, JCM, HD, RR, TP, NV, ME, SE and BM were involved in data collection; JCM and RR interpreted the cytological and histological data; AE and KT did the data analysis; and AE, KT, KD and RH were involved in data interpretation and the drafting of the manuscript. All authors approved the final version of the manuscript.

**Funding.** This research was conducted as part of operational research in the Division of Pulmonology and no dedicated funding was used.

**Conflicts of interest.** None.

- Sheth JS, Belperio JA, Fishbein MC, et al. Utility of transbronchial vs surgical lung biopsy in the diagnosis of suspected fibrotic interstitial lung disease. *Chest* 2017;151(2):389-399. <https://doi.org/10.1016/j.chest.2016.09.028>
- Berbescu EA, Katzenstein A-LA, Snow JL, Zisman DA. Transbronchial biopsy in usual interstitial pneumonia. *Chest* 2006;129(5):1126-1131. <https://doi.org/10.1378/chest.129.5.1126>
- Shim HS, Park MS, Park IK. Histopathologic findings of transbronchial biopsy in usual interstitial pneumonia. *Pathol Int* 2010;60(5):373-377. <https://doi.org/10.1111/j.1440-1827.2010.02528.x>
- Huo YR, Chan MV, Habib AR, Lui I, Ridley L. Pneumothorax rates in CT-guided lung biopsies: A comprehensive systematic review and meta-analysis of risk factors. *Br J Radiol* 2020;93(1108):20190866. <https://doi.org/10.1259/bjr.20190866>
- Peng M, Xu W-b, Shi J-h, et al. [The diagnostic value of CT-guided percutaneous needle lung biopsy in diffuse parenchymal lung diseases]. *Zhonghua Jie He He Hu Xi Za Zhi* 2012;35(3):171-175.
- Blackhall V, Asif M, Renieri A, et al. The role of surgical lung biopsy in the management of interstitial lung disease: Experience from a single institution in the UK. *Interact Cardiovasc Thorac Surg* 2013;17(2):253-257. <https://doi.org/10.1093/icvts/ivt217>
- Nguyen W, Meyer KC. Surgical lung biopsy for the diagnosis of interstitial lung disease: A review of the literature and recommendations for optimizing safety and efficacy. *Sarcoidosis Vasc Diffuse Lung Dis* 2013;30(1):3-16.
- Madan K, Mittal S, Hadda V, Mohan A. Cryoprobe transbronchial lung biopsy with flexible bronchoscope using Arndt endobronchial blocker. *Lung India* 2019;36(3):241-243. [https://doi.org/10.4103/lungindia.lungindia\\_35\\_18](https://doi.org/10.4103/lungindia.lungindia_35_18)
- Lentz RJ, Argento AC, Colby TV, Rickman OB, Maldonado F. Transbronchial cryobiopsy for diffuse parenchymal lung disease: A state-of-the-art review of procedural techniques, current evidence, and future challenges. *J Thorac Dis* 2017;9(7):2186-2203. <https://doi.org/10.21037/jtd.2017.06.96>
- Rodrigues I, Estêvão Gomes R, Coutinho LM, et al. Diagnostic yield and safety of transbronchial lung cryobiopsy and surgical lung biopsy in interstitial lung diseases: A systematic review and meta-analysis. *Eur Respir Rev* 2022;31(166):210280. <https://doi.org/10.1183/16000617.0280-2021>
- Korevaar DA, Colella S, Fally M, et al. European Respiratory Society guidelines on transbronchial lung cryobiopsy in the diagnosis of interstitial lung diseases. *Eur Respir J* 2022;60(5):2200425. <https://doi.org/10.1183/13993003.00425-2022>
- Ariza-Protá M, Pérez-Pallarés J, Fernández-Fernández A, et al. Endobronchial ultrasound-guided transbronchial mediastinal cryobiopsy in the diagnosis of mediastinal lesions: Safety, feasibility and diagnostic yield – experience in 50 cases. *ERJ Open Res* 2023;9(2):00448-2022. <https://doi.org/10.1183/23120541.00448-2022>
- Troy LK, Williamson JP. Mediastinal cryobiopsy: Safe and effective but in whom and when? *Lancet Respir Med* 2023;11(3):217-219. [https://doi.org/10.1016/S2213-2600\(22\)00410-6](https://doi.org/10.1016/S2213-2600(22)00410-6)
- Katgi N, Çimen P, Çirak AK, et al. Complication and cost analysis of transbronchial lung cryobiopsy and awake video-assisted thoracic surgery in diagnosis of interstitial lung disease. *Sarcoidosis Vasc Diffuse Lung Dis* 2022;39(1):e2022005. <https://doi.org/10.36141/svdl.v39i1.12293>
- Leslie KO, Gruden JF, Parish JM, Scholand MB. Transbronchial biopsy interpretation in the patient with diffuse parenchymal lung disease. *Arch Pathol Lab Med* 2007;131(3):407-423. <https://doi.org/10.5858/2007-131-407-TBIITP>
- Thiboutot J, Illei PB, Maldonado F, et al. Safety and feasibility of a sheath cryoprobe for bronchoscopic transbronchial biopsy: The FROSTBITE trial. *Respiration* 2022;101(12):1131-1138. <https://doi.org/10.1159/000526876>
- Khot MS, Chakraborti A, Saini JK, et al. Comparison of the diagnostic yield of transbronchial lung biopsies by forceps and cryoprobe in diffuse parenchymal lung disease. *Afr J Thorac Crit Care Med* 2023;29(3):e799. <https://doi.org/10.7196/AJTCCM.2023.v29i3.799>

Received 22 July 2024. Accepted 29 January 2025. Published 28 March 2025.