


The clinical significance of placental histopathological evaluation in the management of high-risk obstetric patients: A cross-sectional retrospective study

R Stevens,¹ MB ChB , N Odell,^{1*} MMed (O&G); R Wadee,^{2*} MMed (Anat Path), PhD

¹ Department of Obstetrics and Gynaecology, Charlotte Maxeke Johannesburg Academic Hospital and Faculty of Health Sciences, University of the Witwatersrand, Johannesburg, South Africa

² Department of Anatomical Pathology, School of Pathology, Faculty of Health Sciences, University of the Witwatersrand/National Health Laboratory Service, Johannesburg, South Africa

* Joint senior authors

Corresponding author: R Stevens (ronwynnelson@gmail.com)

Background. Placental pathologies cause significant morbidity for both mother and fetus, and represent the largest category of causes of intrauterine death. Placental histopathology allows for recognition of treatment opportunities to prevent recurrence of adverse outcomes.

Objectives. To determine the indications for and findings of placental histopathological evaluation and assess the clinical use of the findings in the management of high-risk obstetric patients. A secondary objective was to compare placental histopathological findings of patients with and without pre-eclampsia.

Methods. A cross-sectional retrospective study was performed at Charlotte Maxeke Johannesburg Academic Hospital, South Africa, on patients who had placentas submitted for histological evaluation at the time of delivery (1 June 2018 - 31 May 2019). The clinical indications, histopathology results and proposed follow-up plan in view of those results were analysed.

Results. We assessed 176 placental histopathology reports and hospital records. The most common indications were stillbirth (50.0%), pre-eclampsia (31.1%), late miscarriage (21.6%) and severe fetal distress (15.9%). The most common individual microscopic findings were increased syncytial knots (52.8%), patchy perivillous fibrin (48.9%) and chorioamnionitis (40.3%). The most common cluster diagnoses were maternal vascular malperfusion (51.1%) and ascending infection (35.8%). Of our patient cohort, 55.7% received a follow-up appointment date and 44.3% did not, and 65.3% of patients with a follow-up appointment did not attend it. A management plan for future pregnancies was formulated for only 52.9% of those who attended their follow-up appointment. While statistically significant individual microscopic features were noted in cases of pre-eclampsia, the most important associations were identified between cluster diagnoses such as maternal vascular malperfusion and pre-eclampsia ($p < 0.0001$) and ascending infection and pre-eclampsia ($p = 0.003$).

Conclusion. This study showed that histopathology results are underutilised in formulating future management plans. In high-risk obstetric patients, management options for pregnancies must include review of previous placental histopathology results to prevent further adverse outcomes.

S Afr J Obstet Gynaecol 2023;29(1):e2109. <https://doi.org/10.7196/SAJOG.2023.v29i1.2109>

The placenta is an important component in the maintenance and development of a healthy pregnancy. Any disruption in the structure or function of the placenta may lead to significant maternal and fetal morbidity. Histological examination of the placenta allows clinicians to understand the intrauterine environment of the fetus and the fetal responses to disease, as well as the pathogenesis of maternal pathology during pregnancy. Placental histology is an essential component of the autopsy in cases of fetal and neonatal death, as it provides insight into the cause, predicts the risk of possible recurrence, and provides useful information on treatment opportunities for future pregnancies.^[1]

The Perinatal Problem Identification Program described in the South African *Saving Babies* 2014 - 2016 report^[2] showed that unexplained intrauterine death remains the largest primary obstetric cause of death category of babies weighing >1 000 g (24.4% of all deaths). Of these babies, 33% had a normal birth weight (>2 500 g), and 48% of unexplained intrauterine deaths occurred in women without obstetric complications. Intrapartum

asphyxia was reported to be the most common cause of fresh stillbirths, and prematurity was the most common cause of early neonatal deaths.^[2] The stillbirth rate in Gauteng Province, South Africa (SA), was 18.7/1 000 births in 2019.^[3] Placental histopathology is a key instrument in understanding the causes of perinatal adverse events. A systematic review by Roescher *et al.*^[4] showed that placental lesions are one of the main causes of fetal death, with maternal vascular malperfusion, fetal thrombosis, infection and chronic placental inflammation leading to significant morbidity for mother and fetus. These placental lesions cause reduced placental efficiency and intrauterine fetal growth restriction, which can lead to intrauterine fetal death. A study by Gardosi *et al.*^[5] found that 40% of stillbirths were associated with fetal growth restriction, and this, as well as other diagnoses, can be confirmed on histopathological assessment.

The essential information available from the pathology report has been underutilised in the clinical setting and has become mainly a means of support in litigation cases. A study by Thirumalaikumar

et al.^[6] highlights the essential indications to request placental histopathology as follows: all stillbirths, late miscarriage, severe fetal distress, prematurity, fetal growth restriction, fetal hydrops and maternal pyrexia. Their study also provided management implications for subsequent pregnancies according to the pathology findings to prevent adverse events from recurring. These management propositions include low-dose aspirin and uterine artery Doppler ultrasound in cases of maternal vascular malperfusion, as well as maternal autoimmune testing and intensive pregnancy surveillance in cases of massive perivillous fibrin deposition, villitis of unknown aetiology or fetal thrombotic vasculopathy.^[6] Acute chorioamnionitis (clinical or subclinical/histological) has been shown to have an association with preterm rupture of the membranes, preterm labour and fetal distress, and is a major contributor to neonatal morbidity.^[7] Screening for bacterial vaginosis and group B streptococcal infection, and limiting the number of vaginal examinations during pregnancy, may be useful in preventing premature rupture of the membranes and chorioamnionitis.^[8]

Our retrospective study investigated the use of placental histopathology reports in the clinical setting of a quaternary academic hospital in Gauteng by reviewing the indications for placental histology, the results of the pathology report, the follow-up process and the formulation of subsequent pregnancy management plans in these high-risk obstetric patients. We also compared placental histopathology findings in patients with and without pre-eclampsia.

Methods

This was a retrospective, descriptive study in which all reports for complete placentas of ≥ 12 weeks' gestation, submitted at Charlotte Maxeke Johannesburg Academic Hospital (CMJAH) between 1 June 2018 and 31 May 2019, were reviewed. The Department of Anatomical Pathology at CMJAH receives placental specimens from 12 referring hospitals. In total, 835 placentas were submitted for pathological examination during the study period, of which 199 were from the CMJAH Department of Obstetrics and Gynaecology. Patients who had complete placental specimens submitted for histopathological evaluation and whose hospital records were captured on the hospital's digital medical records system were included in the study. Patients who only had portions of the placental specimen submitted, of ≤ 12 weeks' gestation, and whose hospital records were not available for review, as well as placental specimens submitted from hospitals other than CMJAH, were excluded from the study. Permission to conduct the study was obtained from the University of the Witwatersrand's Human Research Ethics Committee (Medical) (ref. no. M200928). Clinical data extracted from the hospital records included age, parity, gravidity, previous obstetric history, medical history, gestation at delivery, mode of delivery, and indications for placental examination. Other extracted data included whether a follow-up appointment date was given to the patient to review the histopathology results 6 weeks after delivery, whether the follow-up appointment was attended by the patient, and whether a prospective management plan was formulated for future pregnancies. The potential management plans in subsequent pregnancies included early booking and first-trimester ultrasound, uterine artery Doppler ultrasound, low-dose aspirin or low-molecular-weight heparin, maternal autoimmune testing, immunosuppressive therapy, intensive

pregnancy surveillance, early delivery, cervical length screening, lifestyle changes, genetic counselling, and viral or bacterial infection screening. The histopathology findings and the adequacy of the patient history provided in the placental histology request form were obtained from the pathology reports.

Data analysis

Data were entered into a spreadsheet and exported to Stata version 16 (StataCorp, USA) for statistical analysis. Values are presented as means and standard deviations (SDs) for normally distributed data, and otherwise as medians, with categorical variables expressed as frequencies and percentages. Differences between variables were assessed using a χ^2 test for categorical variables. Results were considered statistically significant at $p < 0.05$.

Results

There was a total of 835 placental histopathology reports between 1 June 2018 and 31 May 2019, of which 199 (23.8%) were on specimens submitted from the Department of Obstetrics and Gynaecology at CMJAH and 636 (76.2%) on specimens received from other institutions. Of the 199 CMJAH reports, 176 met the inclusion criteria of the study. The mean (SD) age of the mothers at delivery was 29.41 (6.2) years and the mean gestation at delivery 29.35 (6.69) weeks. Of the mothers, 20.3% had had previous caesarean section deliveries and 16.4% had had previous miscarriages. Previous stillbirth and termination of pregnancy were reported in 4.0% and 6.2% of the mothers, respectively. The past medical history of the mothers was reported as follows: HIV $n=41$ (23.3%), chronic hypertension $n=13$ (7.4%), diabetes mellitus $n=2$ (1.1%), rhesus negative $n=4$ (2.3%), antiphospholipid syndrome $n=3$ (1.7%), sickle cell disease $n=1$ (0.6%), syphilis $n=5$ (2.8%) and tuberculosis positive $n=2$ (1.1%); 111 patients (63.1%) had no known comorbidities. Normal vaginal delivery was the most common mode of delivery, accounting for 121 cases (68.8%), with 46 patients (26.0%) having induction of labour. Caesarean section was reported in 55 cases (31.3%).

The clinical indications for placental histopathological evaluation are listed in Table 1. The most common indications were stillbirth (50.0%), pre-eclampsia (31.1%), late miscarriage (21.6%) and severe fetal distress (15.9%). Other common placental indications were placental abruption (10.8%) and fetal congenital malformation (10.2%). Most placentas in our cohort had more than one indication for histopathological evaluation, so the total number of clinical indications in Table 1 is more than the total number of patients ($n=176$).

Most of the specimens submitted for histopathological evaluation included an adequately described indication for examination and clinical history of the patient (55.6%), which was provided by the requesting physician on the histopathology clinical request form. However, 43.7% of submitted specimens had an inadequate clinical history or indication for examination. Most commonly, gestational age and obstetric and medical history were omitted, which hampered accurate histological evaluation.

The histopathological findings are summarised in Table 2. Most placentas in our cohort had more than one indication for histopathological evaluation, so the total number of pathological findings in Table 2 is more than the total number of cases ($n=176$). The most common macroscopic findings were meconium staining

Table 1. Clinical indications for placental histopathological evaluation relative to the total number of samples (N=176)

Clinical indication	n (%)*
Stillbirth	88 (50.0)
Pre-eclampsia	55 (31.1)
Late miscarriage (12 - 24 weeks' gestation)	38 (21.6)
Severe fetal distress	28 (15.9)
Placental abruption	19 (10.8)
Fetal congenital malformation	18 (10.2)
Prematurity/preterm labour	17 (9.7)
Fetal growth restriction	8 (4.6)
Multiple gestation	5 (2.8)
Early neonatal death	5 (2.8)
Gestational diabetes	3 (1.7)
Low 5-minute Apgar score	3 (1.7)
Antiphospholipid syndrome	3 (1.7)
Tuberculosis infection	2 (1.1)
Placental mass	2 (1.1)
Offensive liquor	2 (1.1)
Maternal pyrexia	1 (0.6)
Morbidly adherent placenta	1 (0.6)
Rhesus isoimmunisation	1 (0.6)
Two-vessel umbilical cord	1 (0.6)
Cord prolapse	1 (0.6)

*Most placentas had more than one indication for placental histopathological evaluation.

Table 2. Histopathological findings relative to the total number of samples (N=176)

Histopathological findings	n (%)*
Macroscopic findings	
Retroplacental clot	22 (12.5)
Meconium staining	55 (31.3)
Umbilical cord hypercoiling	8 (4.6)
Small placenta for gestation	23 (13.1)
Single umbilical artery	3 (1.7)
Microscopic findings	
Increased syncytial knots	93 (52.8)
Meconium-laden macrophages	62 (35.2)
Chorioamnionitis	71 (40.3)
Patchy perivillous fibrin	86 (48.9)
Infarction	68 (38.6)
Increased circulating nucleated red blood cells	29 (16.5)
Chorangiosis	8 (4.6)
Avascular/oedematous villi	20 (11.4)
Villitis	11 (6.3)
Accelerated villous maturation	46 (26.1)
Distal villous hypoplasia	25 (14.2)
Massive perivillous fibrin/maternal floor infarction	2 (1.1)
Intervillositis	9 (5.1)
Excessive autolysis	2 (1.1)
Cluster diagnoses	
Maternal vascular malperfusion	90 (51.1)
Fetal thrombotic vasculopathy	1 (0.6)
Villitis of unknown aetiology	3 (1.7)
Ascending infection	63 (35.8)

*Most placentas had more than one indication for placental histopathological evaluation.

(31.3%) and small placenta for gestation (13.1%). The most common microscopic findings were increased syncytial knots (52.8%), patchy perivillous fibrin (48.9%) and chorioamnionitis (40.3%). The most common cluster diagnoses were maternal vascular malperfusion (51.1%) and ascending infection (35.8%).

Pre-eclampsia was one of the main indications for placental histopathological evaluation and accounted for 31.1% of samples examined. Table 3 summarises the pathological findings related to pre-eclampsia compared with those unrelated to pre-eclampsia. The pathological findings associated with pre-eclampsia that were statistically significant ($p<0.05$) were increased syncytial knots ($p<0.001$), chorioamnionitis ($p=0.017$), patchy perivillous fibrin ($p=0.008$), infarction ($p=0.001$), increased circulating nucleated red blood cells ($p=0.009$), avascular/oedematous villi ($p=0.029$), accelerated villous maturation ($p=0.001$), massive perivillous fibrin deposition ($p=0.035$) and meconium staining ($p=0.017$). Most significant were the associations between the cluster diagnoses maternal vascular malperfusion and pre-eclampsia ($p<0.0001$), and ascending infection and pre-eclampsia ($p=0.003$).

There was a statistically significant association between a diagnosis of pre-eclampsia and specific adverse neonatal outcomes. Stillbirth occurred in 42.1% of patients with pre-eclampsia ($p=0.003$); fetal growth restriction ($p=0.055$) and severe fetal distress ($p=0.067$) were also prevalent in patients with pre-eclampsia, but these were not statistically significant.

Fifty percent ($n=88$) of placentas submitted for histopathological evaluation were assessed due to stillbirth. Of the patients with stillbirths, 37 (42.1%) were diagnosed with pre-eclampsia. The pertinent histopathological findings in stillbirth cases are summarised in Table 4.

The follow-up and management processes after obtaining placental histopathology results are depicted in Fig. 1. Of the 176 patients whose placentas were assessed, 55.7% ($n=98$) were given a follow-up appointment date to review the result, while a fairly large proportion of patients (44.3%) were not given a follow-up appointment date. Of those who did receive a follow-up appointment date, a large proportion (65.3%; $n=64$) did not attend their follow-up appointment, with only 34.7% ($n=34$) attending. The difference between these proportions is statistically significant ($p<0.001$). Of those mothers who attended the follow-up, no management plan for future pregnancies was formulated for 47.1% ($n=16$). Of the 18 mothers who received a management plan, 37.5% were advised to book antenatal care early in their next pregnancy, 12.5% were advised to receive maternal autoimmune testing, 9.4% were referred for genetic counselling, and 6.3% were advised to take low-dose aspirin in their next pregnancy.

Discussion

The most common indication for placental histopathological assessment was stillbirth. CMJAH is a quaternary-level hospital and therefore receives a large proportion of patients diagnosed with intrauterine fetal death in the district. Most of these deaths are unexplained. According to the CMJAH stillbirth protocol, all stillbirths (explained and unexplained) are required to have placentas sent for histopathological evaluation.

Statistically significant pathological findings in placentas associated with pre-eclampsia ($p<0.05$) included maternal vascular malperfusion ($p<0.0001$) and ascending infection ($p=0.003$). A systematic review

Table 3. Stratification of placental histopathological findings with pre-eclampsia

Histopathological findings	No pre-eclampsia (n=121), n (%)	Pre-eclampsia (n=55), n (%)	p-value
Macroscopic findings			
Retroplacental clot	17 (14.0)	5 (9.1)	0.357
Small placenta for gestation	12 (9.9)	11 (20.0)	0.066
Meconium staining	31 (25.6)	24 (43.6)	0.017*
Umbilical cord hypercoiling	5 (4.1)	3 (5.5)	0.696
Single umbilical artery	3 (2.5)	0	0.239
Microscopic findings			
Increased syncytial knots	46 (38.0)	47 (85.4)	<0.001*
Meconium-laden macrophages	38 (31.4)	24 (43.6)	0.115
Chorioamnionitis	56 (46.3)	15 (27.3)	0.017*
Patchy perivillous fibrin	51 (42.2)	35 (63.6)	0.008*
Infarction	34 (28.1)	34 (61.8)	<0.001*
Increased circulating nucleated red blood cells	14 (11.6)	15 (27.3)	0.009*
Chorangiosis	7 (5.8)	1 (1.8)	0.242
Avascular/oedematous villi	18 (14.9)	2 (3.6)	0.029*
Villitis	7 (5.8)	4 (7.3)	0.706
Accelerated villous maturation	21 (17.4)	25 (45.5)	<0.001*
Distal villous hypoplasia	16 (13.2)	9 (16.4)	0.58
Massive perivillous fibrin/maternal floor infarction	0	2 (3.6)	0.035*
Intervillositis	5 (4.1)	4 (7.3)	0.381
Cluster diagnoses			
Maternal vascular malperfusion	43 (35.5)	47 (85.5)	<0.0001*
Fetal thrombotic vasculopathy	1 (0.8)	0	0.499
Villitis of unknown aetiology	1 (0.8)	2 (3.6)	0.182
Ascending infection	52 (43.0)	11 (20.0)	0.003*

*Statistically significant ($p < 0.05$).**Table 4. Summary of pertinent histopathological findings of stillbirth cases with and without pre-eclampsia**

Histopathological findings	Stillbirth with pre-eclampsia (n=37), n (%)	Stillbirth without pre-eclampsia (n=51), n (%)	p-value
Maternal vascular malformation	18 (48.6)	42 (82.3)	0.883
Massive perivillous fibrin deposition	1 (2.7)	1 (1.9)	0.816
Chorioamnionitis	10 (27.0)	28 (54.9)	0.000*

*Statistically significant ($p < 0.05$).

and meta-analysis by Falco *et al.*^[9] showed that the incidence of both placental villous and vascular histopathological lesions was four- to seven-fold higher in pre-eclamptic pregnancies than in normal pregnancies.

Extensive research has been dedicated to identifying measures to prevent pre-eclampsia, although the underlying pathophysiology is not entirely understood.^[9] However, there is increasing evidence suggesting that suboptimal trophoblastic invasion leads to an imbalance of angiogenic and antiangiogenic proteins, ultimately causing widespread inflammation and endothelial damage.^[10] It has been shown that aspirin at doses <300 mg selectively and irreversibly inactivates the cyclo-oxygenase-1 enzyme, suppressing the production of prostaglandins and thromboxane and inhibiting inflammation and platelet aggregation.^[11] Numerous randomised trials have been published on the safety of the use of aspirin in pregnancy and the inconsistent effects of aspirin on rates of pre-eclampsia. Recently, the Aspirin for Evidence-Based Preeclampsia Prevention trial has revealed that aspirin at a daily dose of 150 mg, initiated before 16 weeks of gestational age, administered at night to a high-risk population identified by a combined first-trimester screening test, reduces the incidence of preterm pre-eclampsia by 62%.^[11,12]

Pre-eclampsia is characterised by abnormal placental formation, which results in inadequate uteroplacental blood flow. Doppler ultrasonography can be used to assess the velocity of the uterine artery blood flow, where persistence of a diastolic notch (beyond 24 weeks' gestation) or abnormal flow velocity ratios (indicated by a mean pulsatility index above the 95th centile) have been associated with inadequate trophoblastic invasion. Studies investigating the predictive accuracy of uterine artery Doppler indices have shown varied results. However, the pulsatility index and bilateral notching are the most promising Doppler indices and should be used in daily clinical practice to identify those patients with an increased risk for developing pre-eclampsia.^[13]

The use of low-dose aspirin before 16 weeks' gestation, as well as uterine artery Doppler ultrasonography in the second trimester of subsequent pregnancies, should be considered in patients who have had placental lesions suggestive of pre-eclampsia, such as inflammation and endothelial damage, increased platelet aggregation, thrombotic events and placental infarcts. This management may prevent recurrent adverse outcomes such as stillbirth, intrauterine growth restriction and preterm delivery due to pre-eclampsia.^[12,13] There was a statistically significant association between the number of patients diagnosed with pre-eclampsia and stillbirth. Stillbirth occurred in 42.1% of patients diagnosed with pre-eclampsia ($p=0.003$). The main histopathological finding in patients with stillbirth was maternal vascular malformation (47.7% of stillbirths). However, 20.5% of these patients were diagnosed with pre-eclampsia. In the stillbirth group, there was no statistically significant association between maternal vascular malformation or massive perivillous fibrin deposition and pre-eclampsia ($p=0.883$ and $p=0.818$, respectively). However, there was a statistically significant association between chorioamnionitis and pre-eclampsia in the stillbirth group ($p < 0.000$). To the best of the authors' knowledge, these three parameters (chorioamnionitis, pre-eclampsia and stillbirth) have not been fully *simultaneously* investigated. Further research into the association between them is suggested for future studies.

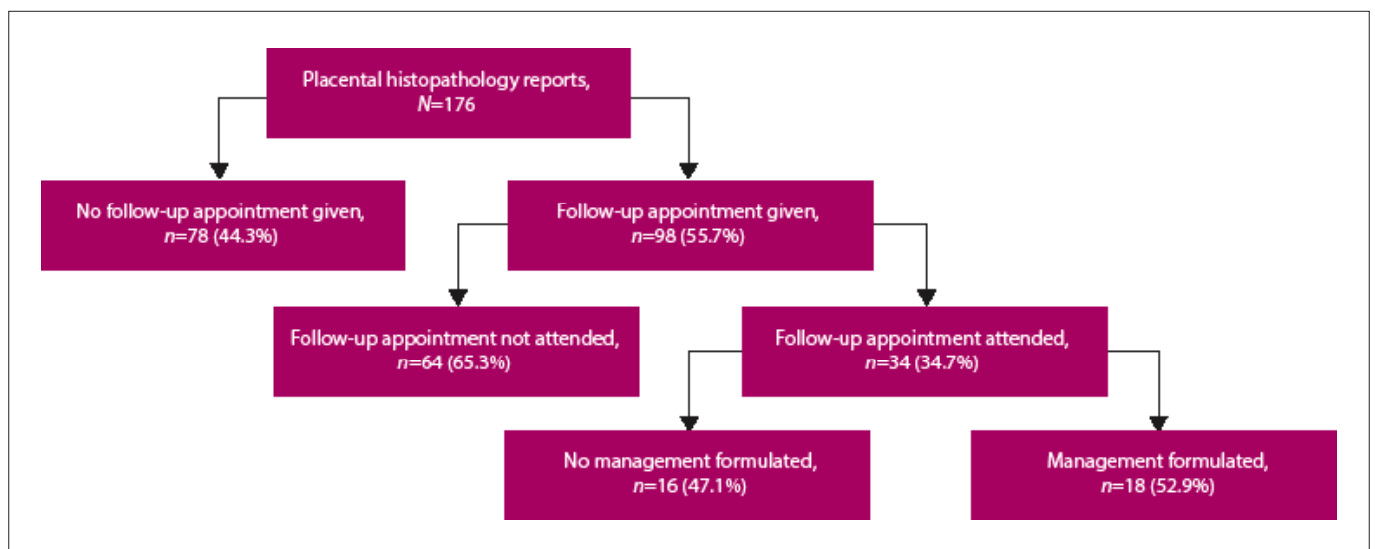


Fig. 1. Flow chart showing the follow-up and management processes after obtaining placental histopathology results.

In some instances, the original pathology reports only included microscopic findings of chorioamnionitis, but these findings were not always incorporated into the final diagnosis. This lack accounts for the discrepancy between identification of chorioamnionitis and the cluster diagnosis of ascending infection. Furthermore, a diagnosis of chorioamnionitis may vary from subchorionic micro-abscess formation to funisitis, and there may be occasions where pathologists mention the presence of chorioamnionitis in the microscopic description but do not include it in the final diagnosis. Placentas at CMJAH are reported on by different pathologists in the department, who have varied placental pathology expertise and interests. As this study aimed to assess pathology reports in relation to clinical outcome, the original tissue sections were not reviewed.

Our study reveals that the placental histopathology report is underutilised, as nearly half of the patients who had placentas submitted for histopathological evaluation in our study did not receive a follow-up appointment date to review their results. Furthermore, the majority of those who received a follow-up date did not attend their appointment. These findings ultimately show that most placental pathology reports during the period under review were not reviewed by a physician and were therefore of no clinical use. Nonetheless, the pathology report is always available for review in subsequent pregnancies of these patients, and highlights areas for intervention.

Study strengths and limitations

This study has clinical relevance and illustrates the need for more attention to be paid to placental pathology reports. The value of communication between clinicians and pathologists is highlighted.

The study was retrospective and was dependent on appropriate physician note-taking and the hospital archiving system. CMJAH is a quaternary referral hospital and therefore receives complicated pregnancies, which may not necessarily reflect the burden of placental disease in clinical practice across all medical facilities. The pathological diagnoses were determined by various pathologists assessing each case, who have varied interests and experience in placental pathology. Pathologists who examine placentas infrequently may not combine all microscopic findings into cluster diagnoses. Use of reporting templates may increase diagnostic accuracy and improve communication of clinically helpful diagnoses.

Conclusion

The placenta provides great insight into the intrauterine environment of the fetus. It has allowed us to identify causes of adverse outcomes and therefore provides opportunities for prevention of recurrence of these outcomes. Communication between clinicians and pathologists should be encouraged, such as at combined interdepartmental multidisciplinary meetings, where pathological findings and clinical management may be discussed. This process will prompt clinicians to review pathology reports in a timely manner. In high-risk obstetric patients, management options for pregnancies must include review of previous placental histopathology results to prevent further adverse outcomes.

Declaration. The research for this study was done in partial fulfilment of the requirements for RS's MMed (O&G) degree at the University of the Witwatersrand.

Acknowledgements. We thank the Epidemiology and Biostatistics Division of the Wits School of Public Health, particularly Dr Zvifadzo Matsena-Zingoni. We also thank the National Health Laboratory Service for assistance in providing patient histopathology reports.

Author contributions. RS prepared the research protocol and collected, analysed and interpreted the data. NO and RW supervised the study and critically reviewed the manuscript.

Funding. None.

Conflicts of interest. None.

- Romero R, Yeon M, Pacora P, et al. The frequency and type of placental histologic findings in term pregnancies with normal outcome. *J Perinat Med* 2018;46(6):613-630. <https://doi.org/10.1515/jpm-2018-0055>
- Gebhardt S, Rhoda N. Saving Babies 2014 - 2016: Triennial report on perinatal mortality in South Africa. Pretoria: National Department of Health, 2018. https://www.westerncape.gov.za/assets/departments/health/napemmco_triennial_report_2014-2016_saving_babies.pdf (accessed 9 March 2023).
- National Department of Health, South Africa. Saving Mothers and Babies 2017 - 2019: Executive summary. 2020. <https://www.samedical.org/file/2007> (accessed 4 April 2023).
- Roescher A, Timmer A, Erwich J, Bos A. Placental pathology, perinatal death, neonatal outcome, and neurological development: A systematic review. *PLoS ONE* 2014;9(2):e89419. <https://doi.org/10.1371/journal.pone.0089419>
- Gardosi J, Mul T, Mongelli M, Fagan D. Analysis of birthweight and gestational age in antepartum stillbirths. *Br J Obstet Gynaecol* 1998;105(5):524-530. <https://doi.org/10.1111/j.1471-0528.1998.tb10153.x>
- Thirumalaikumar L, Ramalingam K, Marton T. Placental histopathological abnormalities and poor perinatal outcomes. *Obstetrician Gynaecologist* 2019;21(2):135-142. <https://doi.org/10.1111/tog.12555>
- Goldenberg R, Culhane J, Iams J, Romero R. Epidemiology and causes of preterm birth. *Lancet* 2008;371(9606):75-84. [https://doi.org/10.1016/S0140-6736\(08\)60074-4](https://doi.org/10.1016/S0140-6736(08)60074-4)

RESEARCH

8. Tita T, Andrews W. Diagnosis and management of clinical chorioamnionitis. *Clin Perinatol* 2010;37(2):339-354. <https://doi.org/10.1016/j.clp.2010.02.003>
9. Falco M, Sivanathan J, Laoreti A, Thilaganathan B, Khalil A. Placental histopathology associated with pre-eclampsia: Systematic review and meta-analysis. *Ultrasound Obstet Gynecol* 2017;50(3):295-301. <https://doi.org/10.1002/uog.17494>
10. Gathiram P, Moodley J. Pre-eclampsia: Its pathogenesis and pathophysiology. *Cardiovasc J Afr* 2016;27(2):71-78. <https://doi.org/10.5830/CVJA-2016-009>
11. Rolnik D, Wright D, Poon L, et al. ASPRE trial: Performance of screening for preterm pre-eclampsia. *Ultrasound Obstet Gynecol* 2017;50(4):492-495. <https://doi.org/10.1002/uog.18816>
12. Rolnik D, Nicolaides K, Poon L. Expert Review: Prevention of preeclampsia with aspirin. *Am J Obstet Gynecol* 2022;226(2S):S1108-S1119. <https://doi.org/10.1016/j.ajog.2020.08.045>
13. Cnossen JS, Morris RK, ter Riet G, et al. Use of uterine artery Doppler ultrasonography to predict pre-eclampsia and intrauterine growth restriction: A systematic review and bivariable meta-analysis. *CMAJ* 2008;178(6):701-711. <https://doi.org/10.1503/cmaj.070430>

Accepted 24 January 2023.